

Use of Acellular Dermal Matrix Following Fasciectomy for the Treatment of Dupuytren's Disease

Don Hoang, MD*
 Patrick Steven, BS*
 Vivi W. Chen, BS*
 Ashley Stasiak, MD*
 Myles Cohen, MD*†
 David A. Kulber, MD*†

Background: Recurrence rates following surgical intervention for Dupuytren's disease (DD) remains high. In this study, we investigate the use of acellular dermal matrix (ADM) to reduce recurrence and improve long-term clinical outcome.

Methods: We examined 132 patients undergoing open fasciectomy for DD from 2007 to 2017. The experimental group had a sheet of ADM (FlexHD) sutured into the surgical bed controls were not closed with ADM. Patient characteristics, range of motion, and complications were examined.

Results: Twenty-eight (21.2%) patients were treated with acellular dermal matrix, whereas 104 (78.8%) patients were not. The median age was 67.0 years (range 34–91 years), with no differences between group regarding age, comorbidities, and laterality. The mean preoperative interphalangeal joint flexion contracture in the ADM group of 66.5 ± 29.9 degrees was corrected to 9.7 ± 12.4 degrees, whereas the mean metacarpophalangeal joint preoperative flexion contracture of 51.4 ± 23.9 degrees was corrected to 7.8 ± 14.1 degrees at postoperative examination ($P < 0.05$). The median follow-up was 18.7 months, during which the recurrence of contracture was observed in 1 of 28 patients in the group receiving ADM compared with 9 of 104 in the control group ($P = 0.37$). There were no differences in the incidence of minor wound complications observed.

Conclusion: The adjunct placement of acellular dermal matrix into the wound bed following fasciectomy for DD may be an important surgical strategy to reduce recurrence rates as well as augment coverage of exposed vital structures in cases of severe flexion contracture. (*Plast Reconstr Surg Glob Open* 2019;7:e2263; doi: 10.1097/GOX.0000000000002263; Published online 28 May 2019.)

INTRODUCTION

An inheritable disorder of autosomal dominance, Dupuytren's disease (DD) is a common fibroproliferative disorder causing flexion contractures of the hand. It is known to affect individuals between the fifth and seventh decades, with a geographical distribution that broadly follows the migration patterns of Northern Europeans

around the globe.¹ Most commonly DD involves contracture of the small finger, with a single digit involved in 60% of the patients.² The tissue in DD is composed of cords, consisting of scanty fibroblasts, and nodules, consisting of whorls of cells. The contractile ability of the disease is the result of myofibroblasts' cells that are otherwise typically seen in normal wound healing. In DD, the formation of nodules and cords progresses from an initial cellular proliferative stage, through an intermediate fibrocellular stage, to a terminal fibrotic stage.³

A contracture that interferes with function is the most common indication for surgical intervention. Various surgical treatment modalities exist, such as fasciotomy, fasciectomy, and dermofasciectomy. However, recurrence rates remain high following surgical treatment, which ranges from 12% to 39%. In 1979, Rudolph⁴ demonstrated that myofibroblasts are inhibited by the presence of full-thickness skin grafts, and in 1993, McCann et al observed that in a large proportion of samples from patients with DD, myofibroblasts were found to be extending into the dermis.^{5,6} These findings may demonstrate why procedures

From the *Department of Plastic and Reconstructive Surgery, Keck School of Medicine, University of Southern California, Los Angeles, Calif.; and †Center for Plastic and Reconstructive Surgery, Cedars-Sinai Medical Center, Los Angeles, Calif.

Presented at the American Society for Surgery of the Hand (ASSH), 2018, Phoenix, Arizona.

Received for publication June 18, 2018; accepted March 26, 2019.

Copyright © 2019 The Authors. Published by Wolters Kluwer Health, Inc. on behalf of The American Society of Plastic Surgeons. This is an open-access article distributed under the terms of the Creative Commons Attribution-Non Commercial-No Derivatives License 4.0 (CCBY-NC-ND), where it is permissible to download and share the work provided it is properly cited. The work cannot be changed in any way or used commercially without permission from the journal.

DOI: 10.1097/GOX.0000000000002263

Disclosure: The authors have no financial interest to declare in relation to the content of this article.

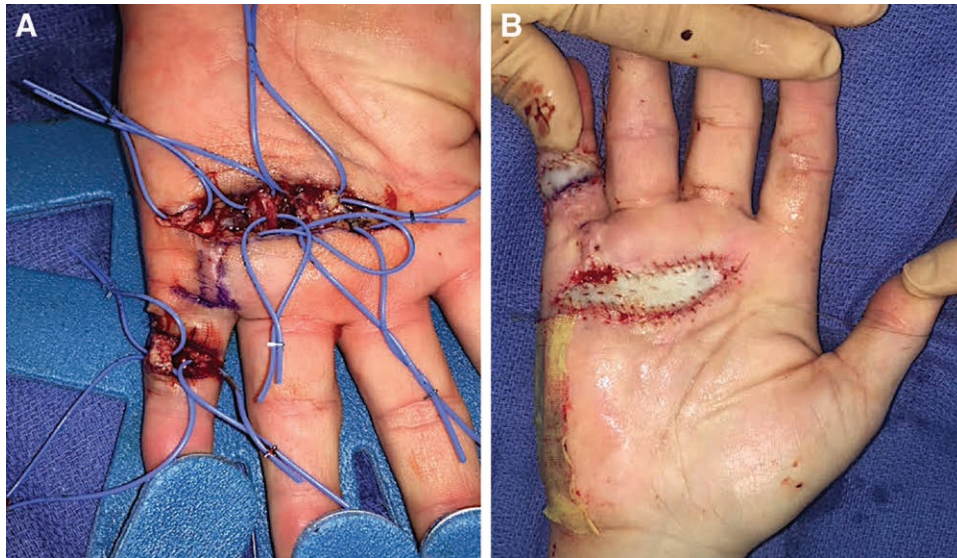


Fig. 1. Intraoperative view of (A) fasciectomy and ADM inset into (B) fasciectomy wound.

that leave the overlying dermis intact have a high recurrence rate, possibly due to the abnormal interaction between the overlying dermis and underlying connective tissue layers in the development of DD. Previous studies demonstrate recurrence rates as low as 12.2% with use of a full-thickness skin graft and <5% with use of acellular dermal matrix (ADM) as reported by a single study.⁷ In this study, we aimed to further evaluate the use of ADM to reduce recurrence rates based on the postulate that ADM has an inhibitory effect on underlying myofibroblasts.

METHODS

We performed a retrospective cohort study of 132 patients undergoing open fasciectomy for DD from years 2007 to 2017 performed by a single surgeon (DK) at our academic institution. Only patients with symptomatic DD with the presence of nodules and/or joint contracture were included in this study.

Standard McCash technique fasciectomies of affected palmar and digital fascia were performed. Patients in the experimental group had a sheet of ADM (FlexHD; Musculoskeletal Transplant Foundation, Edison, NJ) sutured into the surgical bed with absorbable sutures (Fig. 1), whereas patients in the control group were not closed with ADM. ADM was utilized in place of a full-thickness skin graft. The thickness of the ADM was not measured in each patient, but product specifications were followed from manufacturer (Table 1). Patients in the control group were not closed with acellular dermal matrix but instead were allowed to heal by secondary intention. Patients were then evaluated at follow-up for disease recurrence, defined as the presence of Dupuytren tissue in an area previously operated on with a contracture greater than that recorded following the surgical fasciectomy, or presence of contracture requiring surgery.

Table 1. Structure and Dimension of ADM

FlexHD Structural Thin	
Tissue Code	Product Specifications
470102	FlexHD structural, thin: 1 cm (W) × 2 cm (L) × 0.4–0.8 mm thick
470204	FlexHD structural, thin: 2 cm (W) × 4 cm (L) × 0.4–0.8 mm thick
470307	FlexHD structural, thin: 3 cm (W) × 7 cm (L) × 0.4–0.8 mm thick
470407	FlexHD structural, thin: 4 cm (W) × 7 cm (L) × 0.4–0.8 mm thick

Statistical Analyses

Bivariate analysis was performed using the chi-square test. Wilcoxon signed rank test and Mann–Whitney test were used to determine statistical differences between the paired pre- and postoperative measurements. *P* values were two-tailed, and values ≤0.05 were defined as statistically significant.

RESULTS

Results are detailed in Table 2. Among the cohort of 132 patients, 28 (21.2%) patients were treated with acellular dermal matrix (Figs. 2, 3), whereas 104 (78.8%) patients were not. The median age was 67.0 years (range 34–91 and 39–82 years in the control and dermal matrix groups, respectively). No statistical difference existed between each group regarding age, comorbidities, and laterality. The most common comorbidity was a smoking history, with 34% in the control group versus 43% in the dermal matrix group. There was no significant difference between each group regarding the type of previous treatments, such as collagenase and surgery. Distribution of the affected area was similar except for increased involvement of the small finger in the ADM group (*P* = 0.002).

The mean preoperative interphalangeal joint flexion contracture in the ADM group of 66.5 ± 29.9 degrees was

corrected to 9.7 ± 12.4 degrees, whereas the mean metacarpophalangeal joint preoperative flexion contracture of 51.4 ± 23.9 degrees was corrected to 7.8 ± 14.1 degrees at postoperative examination ($P < 0.05$). The median follow-up was 18.7 months, during which the recurrence of contracture was observed in 1 of 28 patients in the group receiving ADM, compared with 9 of 104 in the control group ($P = 0.37$). Of all patients, 2 complications occurred in the control group—infection and complex regional pain syndrome. There were no differences in the incidence of complications observed.

DISCUSSION

Ongoing debate exists regarding the optimal surgical method in treating DD—whether to utilize traditional open fasciectomy, limited procedures, or less invasive techniques, as well as when to use alternative operative techniques such as wide-awake open release and 2-stage treatments.⁸ Reported recurrence rates for open fasciectomy in treating DD varies widely within current literature. Multiple large studies with long-term follow-up suggest that these traditional procedures are associated with high recurrence rates, from 39% following fasciectomy to 62% following fasciotomy.⁹ Hueston^{10,11} reported in 1962 and 1969 the observation of no recurrences in patients who underwent full-thickness excision of skin and diseased fascia and full-thickness skin grafting, later termed dermofasciectomy. Since then, additional studies demonstrate the lower recurrence rates for dermofasciectomy,^{12–20} further suggesting the association of the dermis overlying the diseased fascia with disease recurrence. Therefore, it has been hypothesized that a barrier between the wound bed and the overlying dermis could replicate the success rate of dermofasciectomy by blocking the interaction between wound and dermis and thus avoid the disadvantages in excising the skin completely and using full-thickness skin grafts.⁶

Human ADM was released in 1994 for the replacement of inadequate integumental tissue due to burn injury and has since been found useful as skin replacement for its ability to retain elastin and collagen fibers after undergoing decellularization and sterilization.²¹ In a review on the use of ADM in forearm, wrist, and hand reconstruction, Ellis and Kulber²² found that ADM offers innovative utility in solving upper extremity surgical problems, but that more comparative trials are necessary. Nevertheless, little is known about the use of ADM in surgically treating DD and has only previously been studied in small cohorts and implicated as a successful viable alternative to the standard procedure.⁶ In this study, we observed similar results to that of Terry et al.⁶ Although not statistically significant, there was a trend toward lower recurrence rates in the ADM group. The patient history, such as experience with age, laterality, previous surgery, and comorbidities, was similar regardless of treatment group. Interestingly, flexion of the MPJ was significantly better both preoperatively and postoperatively in the dermal matrix group and complication rates were comparable and low to none for both groups. This indicates that ADM is a viable surgical option, but further studies are required, with a larger sample size, to elucidate this option.

Table 2. Characteristics of Control and Acellular Dermal Matrix Patient Cohorts

Treatment of Dupuytren Contracture with Acellularized Dermal Matrix and Control Groups			
Characteristic	Control Group (n = 104)	Dermal Matrix Group (n = 28)	P
Median age (y)	67.00	67.00	1.000
Minimum–maximum (y)	34–91	39–82	
Laterality			0.300
Left	51	10	
Right	51	17	
Bilateral	1	1	
Previous treatment	46	16	0.287
Collagenase	10	4	
Surgery	36	12	
Comorbidities			
Diabetes	15	3	0.763
Prostate cancer	4	1	1.000
Beta blocker use	17	1	0.119
Significant alcohol history	9	6	0.088
Smoking history	35	12	0.382
History of seizure disorder	2	0	1.000
Distribution of affected area			
Palm	101	28	1.000
Thumb	11	5	0.330
IF	15	9	0.050
MF	56	17	0.298
RF	72	23	0.238
SF	67	26	0.002
Flexion IPJ contracture (degrees)			
Preoperative mean	50.5	66.5	0.007
Postoperative mean	2.1	9.7	0.002
Mean improvement	48.4	56.8	0.194
Flexion MPJ contracture (degrees)			
Preoperative mean	41.7	51.4	0.069
Postoperative mean	0.5	7.8	0.018
Mean improvement	41.3	43.6	0.617
Median follow-up (mo)			
Minimum–maximum (mo)	52.06	18.73	0.001
Recurrence	9 (9%)	1 (4%)	0.368
Complications			
Infection	1	0	
Hematoma	0	0	
CRPS	1	0	
Nerve injury	0	0	
Devascularized digit	0	0	
Skin necrosis	0	0	

IF, MF, RF, SF: IF, index finger; MF, middle finger; RF, ring finger; SF, small finger; CRPS, complex regional pain syndrome; IPJ, interphalangeal joint; MPJ, metacarpophalangeal joint.

As such, our study is not without limitations, with an unequal distribution of patients between the experimental and control groups. Furthermore, the experimental ADM group had shorter follow-up and fewer patients than the control group. However, we hope that these results can lead to a prospective double-blinded study that can further elucidate surgical treatment utilizing ADM for DD. An ideal future study can involve a prospective study of greater power with similar duration, longer follow-up, and an additional control group with skin grafting.

Overall, we found that the adjunct placement of acellular dermal matrix into the wound bed following fasciectomy for DD may be an important surgical strategy to reduce recurrence rates as well as augment coverage of exposed vital structures in cases of severe flexion contracture.

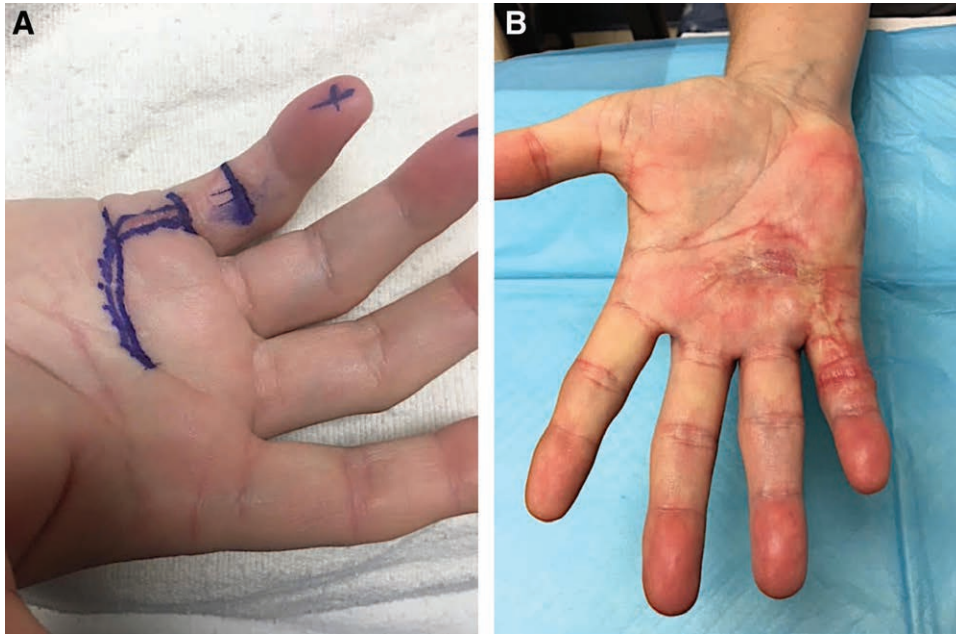


Fig. 2. Closure with ADM of palm and fifth digit.(A) Preoperative and (B) postoperative views of palm and fifth digit closed with ADM.

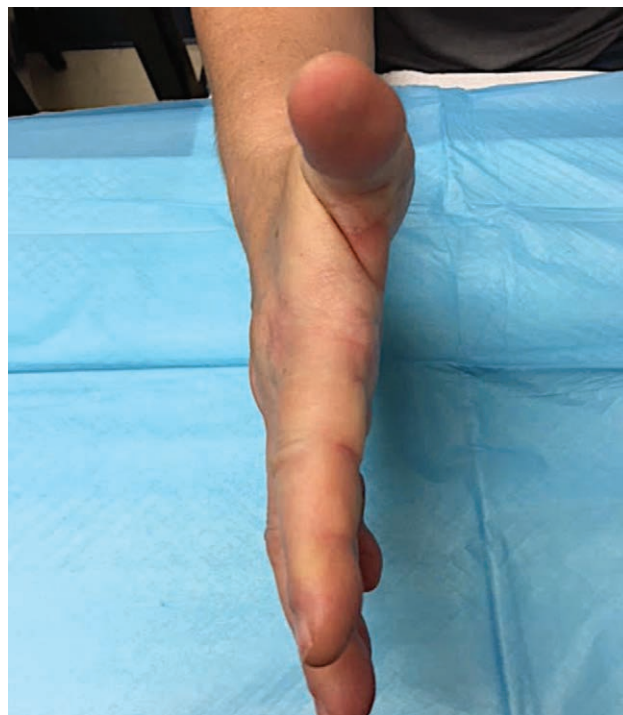

Fig. 3. Postoperative view of patient showing improved range of motion (ROM).

David A. Kulber, MD

Director, Center for Plastic and Reconstructive Surgery
 Professor, Surgery
 Director, Plastic Surgery Center, Cedars-Sinai Medical Group
 Address: 8635 W. Third St.
 Suite 990W
 Los Angeles, CA 90048
 Cedars-Sinai Medical Center
 Los Angeles, CA
 E-mail: David.Kulber@cshs.org

REFERENCES

1. Birks M, Bhalla A. Dupuytren's disease. *Surgery*. 2013;31:177–e180.
2. Dias JJ, Braybrooke J. Dupuytren's contracture: an audit of the outcomes of surgery. *J Hand Surg Br*. 2006;31:514–521.
3. Balaguer T, David S, Ihrai T, et al. Histological staging and Dupuytren's disease recurrence or extension after surgical treatment: a retrospective study of 124 patients. *J Hand Surg Eur Vol*. 2009;34:493–496.
4. Rudolph R. Inhibition of myofibroblasts by skin grafts. *Plast Reconstr Surg*. 1979;63:473–480.

5. McCann BG, Logan A, Belcher H, et al. The presence of myofibroblasts in the dermis of patients with Dupuytren's contracture. A possible source for recurrence. *J Hand Surg Br*. 1993;18:656–661.
6. Terry MJ, Sue GR, Goldberg C, et al. Hueston revisited: use of acellular dermal matrix following fasciectomy for the treatment of Dupuytren's disease. *Ann Plast Surg*. 2014;73(suppl 2):S178–S180.
7. Ullah AS, Dias JJ, Bhowal B. Does a 'firebreak' full-thickness skin graft prevent recurrence after surgery for Dupuytren's contracture?: a prospective, randomised trial. *J Bone Joint Surg Br*. 2009;91:374–378.
8. Sweet S, Blackmore S. Surgical and therapy update on the management of Dupuytren's disease. *J Hand Ther*. 2014;27:77–83; quiz 84.
9. Crean SM, Gerber RA, Le Graverand MP, et al. The efficacy and safety of fasciectomy and fasciotomy for Dupuytren's contracture in European patients: a structured review of published studies. *J Hand Surg Eur Vol*. 2011;36:396–407.
10. Hueston JT. Digital Wolfe grafts in recurrent Dupuytren's contracture. *Plast Reconstr Surg Transplant Bull*. 1962;29:342–344.
11. Hueston JT. The control of recurrent Dupuytren's contracture by skin replacement. *Br J Plast Surg*. 1969;22:152–156.
12. Abe Y, Rokkaku T, Kuniyoshi K, et al. Clinical results of dermofasciectomy for Dupuytren's disease in Japanese patients. *J Hand Surg Eur Vol*. 2007;32: 407–410.
13. Armstrong JR, Hurren JS, Logan AM. Dermofasciectomy in the management of Dupuytren's disease. *J Bone Joint Surg Br*. 2000;82:90–94.
14. Brotherston TM, Balakrishnan C, Milner RH, et al. Long term follow-up of dermofasciectomy for Dupuytren's contracture. *Br J Plast Surg*. 1994;47:440–443.
15. Hall PN, Fitzgerald A, Sterne GD, et al. Skin replacement in Dupuytren's disease. *J Hand Surg Br*. 1997;22:193–197.
16. Kelly SA, Burke FD, Elliot D. Injury to the distal radius as a trigger to the onset of Dupuytren's disease. *J Hand Surg Br*. 1992;17:225–229.
17. Logan AM, Brown HG, Lewis-Smith P. Radical digital dermofasciectomy in Dupuytren's disease. *J Hand Surg Br*. 1985;10:353–357.
18. Ketchum LD, Hixson FP. Dermofasciectomy and full-thickness grafts in the treatment of Dupuytren's contracture. *J Hand Surg Am*. 1987;12(5 pt 1):659–664.
19. Tonkin MA, Burke FD, Varian JP. Dupuytren's contracture: a comparative study of fasciectomy and dermofasciectomy in one hundred patients. *J Hand Surg Br*. 1984;9:156–162.
20. Searle AE, Logan AM. A mid-term review of the results of dermofasciectomy for Dupuytren's disease. *Ann Chir Main Memb Super*. 1992;11:375–380.
21. Musculoskeletal Transplant Foundation and Ethicon. FlexHD (brochure); 2010.
22. Ellis CV, Kulber DA. Acellular dermal matrices in hand reconstruction. *Plast Reconstr Surg*. 2012;130(5 suppl 2):256S–269S.